

FRACTURES OF THE FIFTH METATARSAL



American College of
Foot and Ankle Surgeons

What is a Fifth Metatarsal Fracture?

Fractures (breaks) are common in the fifth metatarsal—the long bone on the outside of the foot that connects to the little toe. Two types of fractures that often occur in the fifth metatarsal are:

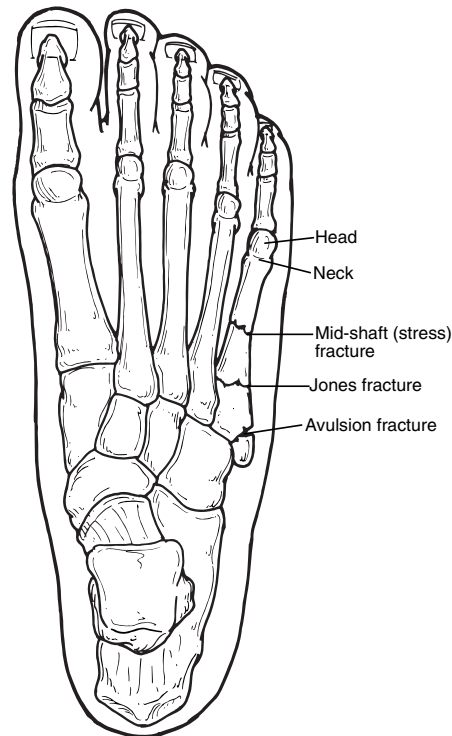
- **Avulsion fracture.** In an avulsion fracture, a small piece of bone is pulled off the main portion of the bone by a tendon or ligament. This type of fracture is the result of an inversion injury, in which the ankle rolls inward. Avulsion fractures are often overlooked when they occur with an ankle sprain.
- **Jones fracture.** Jones fractures occur in a small area of the fifth metatarsal that receives less blood and is therefore more prone to injury. A Jones fracture can be either a stress fracture (a tiny hairline break that occurs over time) or an acute (sudden) break. Jones fractures are caused by overuse, repetitive stress, or trauma. They are less common and more difficult to treat than avulsion fractures.

Other types of fractures can occur in the fifth metatarsal. Examples include mid-shaft fractures, which usually result from trauma or twisting, and fractures of the metatarsal head and neck.

Signs and Symptoms

Avulsion and Jones fractures have the same signs and symptoms. These include:

- Pain, swelling, and tenderness on the outside of the foot
- Difficulty walking
- Bruising may occur



Diagnosis

Anyone who has symptoms of a fifth metatarsal fracture should see a foot and ankle surgeon as soon as possible for proper diagnosis and treatment. To arrive at a diagnosis, the surgeon will ask how the injury occurred or when the pain started. The foot will be examined, with the doctor gently pressing on different

areas of the foot to determine where there is pain.

The surgeon will also order x-rays. Because a Jones fracture sometimes does not show up on initial x-rays, additional imaging studies may be needed.

Treatment

When it is not possible to see a foot and ankle surgeon immediately, the “R.I.C.E.” method of care should be performed. This involves:

- **Rest.** It is crucial to stay off the injured foot, since walking can cause further damage.
- **Ice.** To reduce swelling and pain, apply a bag of ice over a thin towel to the affected area for 20 minutes of each waking hour. Do not put the ice directly against the skin.
- **Compression.** Wrap the foot in an elastic bandage or wear a compression stocking to prevent further swelling.
- **Elevation.** Keep the foot elevated to reduce the swelling. It should be even with or slightly above the hip level.

Options for treatment of an avulsion fracture may include:

- **Immobilization.** Depending on the severity of the injury, the foot is kept immobile with a cast, cast boot, or stiff-soled shoe. Crutches may also be needed to avoid placing weight on the injured foot.

- **Surgery.** If the injury involves a displaced bone, multiple breaks, or has failed to adequately heal, surgery may be needed.

Options for treatment of a Jones fracture may include:

- **Immobilization.** As with avulsion fractures, initial treatment may involve immobilization, but typically for a longer period of

time because these fractures take longer to heal.

- **Bone stimulation.** A pain-free external device is used to speed the healing of some fractures. Bone stimulation may be used as part of the treatment or following an inadequate response to immobilization.
- **Surgery.** Surgery may be needed, since Jones fractures often do not

heal through immobilization and bone stimulation.

If surgery is required for treatment of a fifth metatarsal fracture, the foot and ankle surgeon will determine the type of procedure that is best suited to the individual patient. ▲

